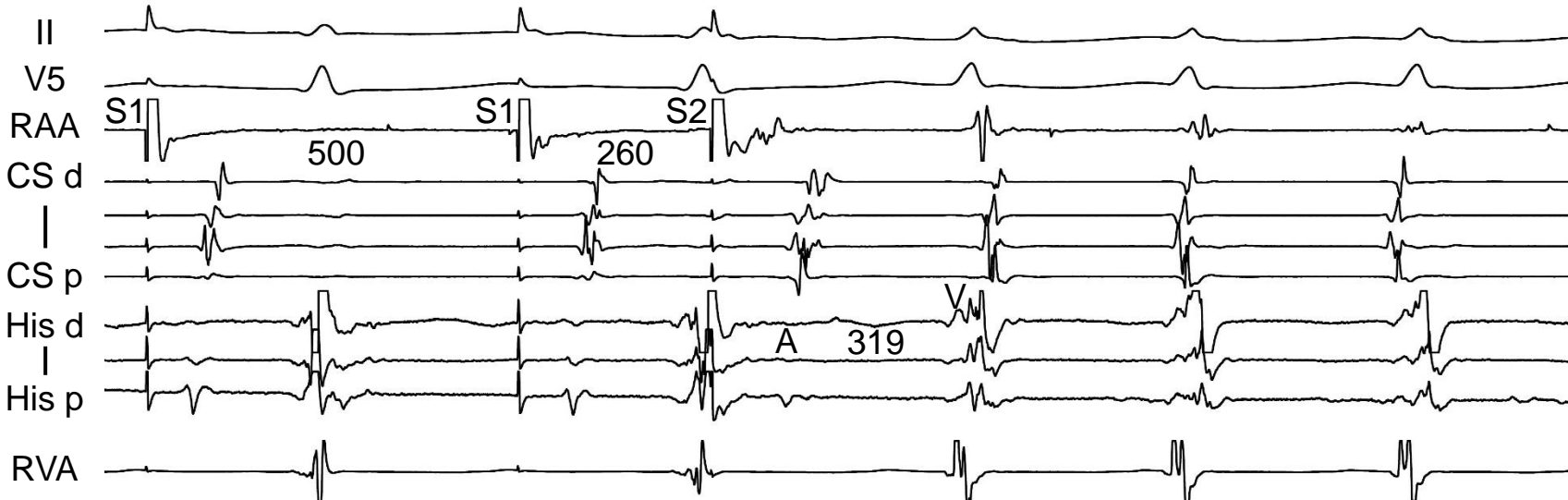
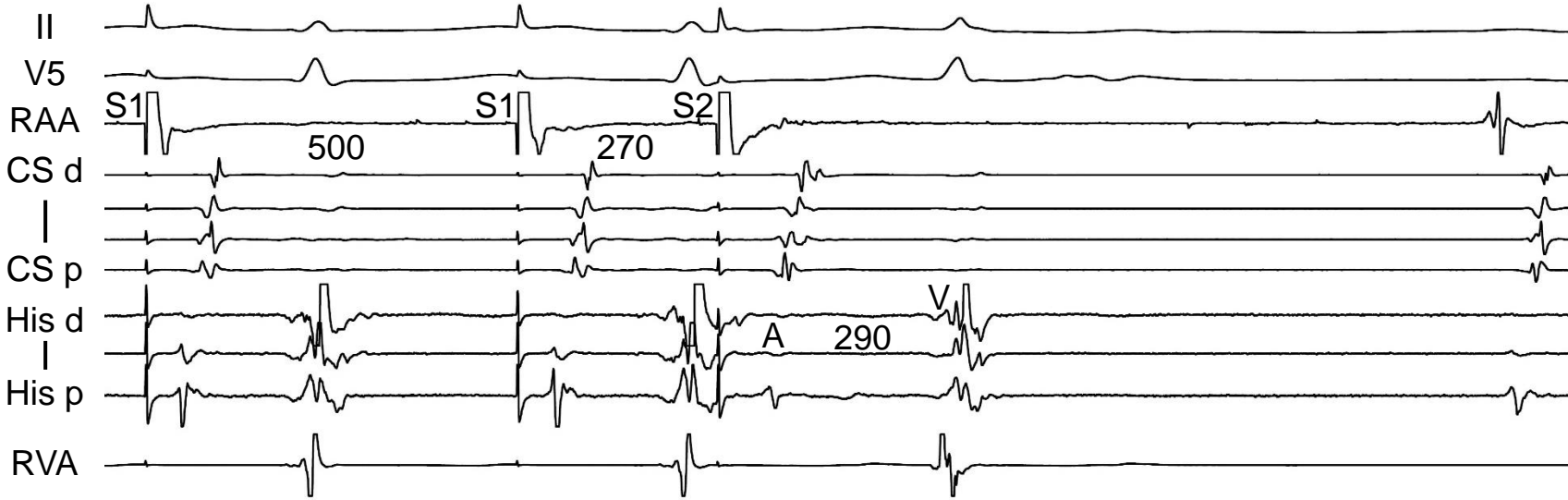


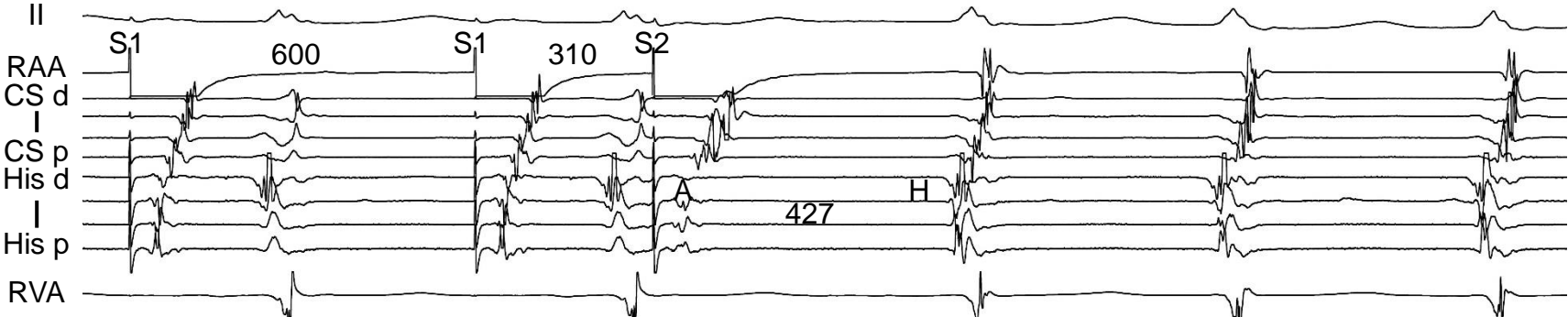
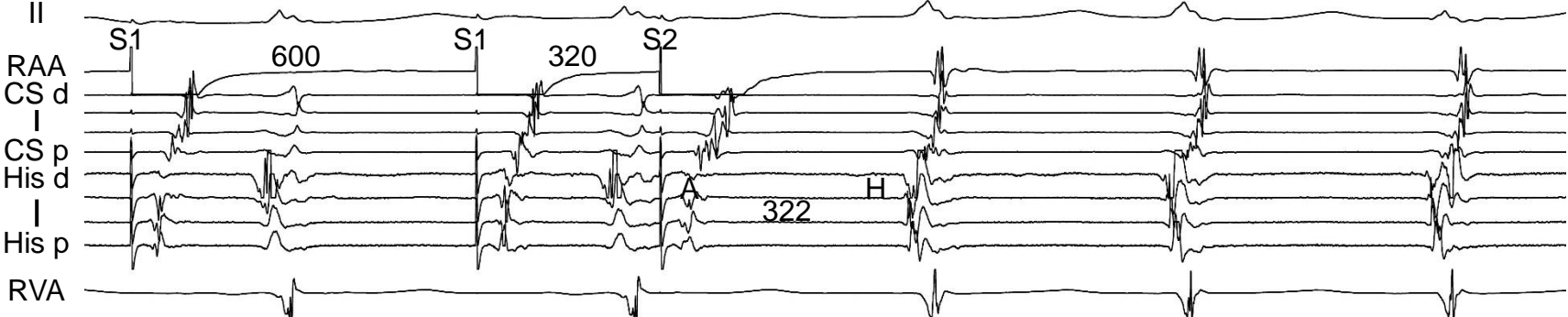
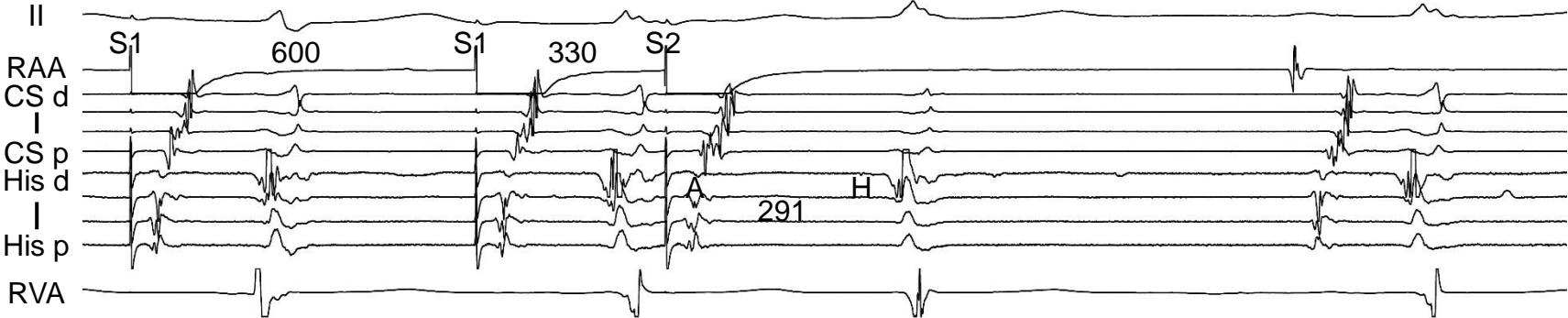
頻拍中に同時相A-Vを示す リエントリー性上室頻拍の3症例

それぞれ頻拍の機序が異なります。
診断は何か考えてみて下さい。

Case 1 : 78 y/o male



Case 2 : 77 y/o male



Case 3 : 51 y/o male

